

Staphylococcus lugdunensis Infection of the Bilateral Axillaries

Ethan Loftspring, BS¹ • Karen Cuartas, BS² • Brandon Hood, MD³ • Doris Lin, MD, MS⁴

Abstract

Background. We present a case of a 29-year-old woman admitted to the hospital with hidradenitis suppurativa and found to have *Staphylococcus lugdunensis* bacteremia. Due to concern for the pathogenicity of this organism and recurrence of her axillary infection, a transthoracic echocardiogram was performed. The results did not demonstrate endocarditis. She was successfully treated with a course of oral doxycycline and topical agents. In contrast to other coagulase-negative staphylococci (CoNS), *S lugdunensis* has been shown to have a virulence pattern rivaling that of *Staphylococcus aureus*. It is important to educate clinicians on prompt management and treatment when patients are found to be bacteremic with this organism, as it can cause deep-seated and suppurative infections.

Key words: hidradenitis suppurativa, *Staphylococcus lugdunensis*, bacteremic

Typical culprits for causing skin and soft tissue infections include *S aureus* and *Streptococcus* species, which normally colonize the skin. Other organisms found to colonize the skin include coagulase-negative staphylococci (CoNS) which are often considered harmless.¹ Since speciation of CoNS has become more common, one species in particular has proven more clinically significant than the rest. *S lugdunensis*, like *S aureus*, has been

known to cause bacteremia, native-valve endocarditis, and severe skin and soft tissue infections. In fact, *S lugdunensis* and *S aureus* share several virulence factors.¹

In this case, we present a patient with hidradenitis suppurativa and isolated *S lugdunensis* bacteremia. We discuss recent literature regarding the relationship between *S lugdunensis* and hidradenitis suppurativa as well as characteristics that make this organism more virulent than

other CoNS. We also emphasize the importance of appropriate management and treatment in patients infected with this organism. Moreover, we suggest reconsidering the pervasive dogma that CoNS simply be considered a contaminant.

Case Presentation

A 29-year-old woman who had received a diagnosis of hidradenitis suppurativa 5 years ago presented to our clinic with a fever and bilateral axillary pain. After several refractory flares, she had undergone bilateral axillary excision of the affected folliculopilosebaceous units and had been in remission for 3 years. Three days prior to presentation, she had presented to an outside hospital and was prescribed oral clindamycin 300 mg every 6 hours for the treatment of cellulitis; however, her symptoms worsened.

Physical examination

Upon arrival at our hospital, the patient was in moderate distress with severe bilateral axillary pain. She had tachycardia with a pulse rate of 134 beats/min and was

AFFILIATIONS:

¹Medical Student, Baylor College of Medicine, Houston, TX

²Medical Student, McGovern Medical School, Houston, TX

³Resident, Baylor College of Medicine, Houston, Texas

⁴Associate Professor, Department of Medicine, Baylor College of Medicine, Houston, TX

CITATION:

Loftspring E, Cuartas K, Hood B, Lin D. *Staphylococcus lugdunensis* infection of the bilateral axillaries. Consultant. Published online July 7, 2022. doi:10.25270/con.2022.07.00006

Received February 11, 2022; accepted March 11, 2022.

DISCLOSURES:

The authors report no relevant financial relationships.

CORRESPONDENCE:

Doris Lin, MD, MS, Baylor College of Medicine, 1504 Taub Loop, 2PA 71009, Houston, TX 77030 (Doris.Lin@bcm.edu)

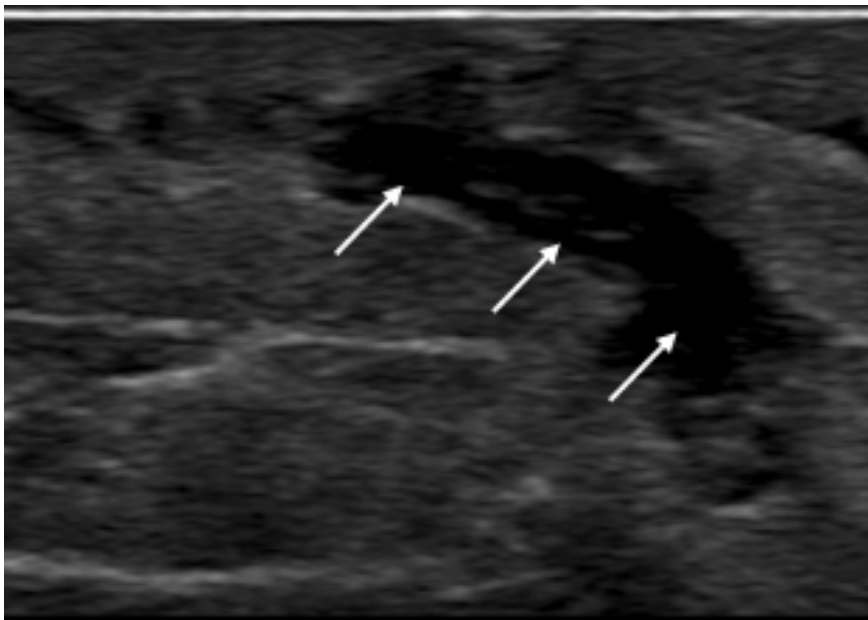


Figure. An ultrasonography scan of the right axilla demonstrated branching anechoic areas (arrows) in the subcutaneous tissues with thickened and echogenic overlying skin layers. No organized abscess collections were present, and increased vascularity was noted on color flow imaging compatible with subcutaneous phlegmon.

febrile with a temperature of 38.2 °C. With the exception of erythematous, indurated axillae that were acutely tender to palpation, the physical examination was otherwise unremarkable.

Diagnostic Testing

Laboratory results were unremarkable except for a white blood cell count of 23.1 K/ μ L. She was admitted to the hospital and empirically started on intravenous vancomycin 1.25 g every 8 hours. An ultrasonography scan revealed a right axillary phlegmon and bilateral cellulitis without a drainable collection, most consistent with hidradenitis suppurativa (**Figure**). Blood cultures grew *Staphylococcus lugdunensis* sensitive to tetracycline. A transthoracic echocardiogram did not show valvular vegetations.

Treatment and management. An infectious disease specialist was consulted and opted to transition from vancomycin to doxycycline based on the antibiotic sensitivity profile of *S lugdunensis*. The patient's symptoms improved, and she was ultimately discharged to complete a 14-day course of oral doxycycline 100 mg twice

daily for bacteremia, in addition to topical clindamycin and benzoyl peroxide for the treatment of hidradenitis suppurativa.

Discussion

Skin and soft tissue infections (SSTIs) involve microbial invasion of the skin and underlying soft tissues. The incidence of SSTIs in the United States has increased significantly and is one of the most common infections encountered in both the inpatient and outpatient settings.^{1,2} Typical culprits for causing SSTIs include *Staphylococcus aureus* and *Streptococcus* species, which are organisms that normally colonize the skin. Other commensal organisms include coagulase-negative staphylococci (CoNS), which are often considered benign. However, one species in particular, *S lugdunensis*, has garnered recent attention in its virulence that may even rival that of *S aureus*. Furthermore, this organism is an emerging pathogen in SSTIs and has been reported to constitute 5% to 6% of CoNS isolated from various skin lesions,³ and an even higher rate of isolation has been reported from patients with hidradenitis suppurativa.⁴ In a pro-

spective study conducted by Guet-Revillet and colleagues,⁴ this pathogen was cultured and isolated as the main organism in 58% of hidradenitis suppurativa nodules and abscesses. Here, we present a patient with hidradenitis suppurativa and *S lugdunensis* bacteremia. Our aim is to educate clinicians on the association of this organism with SSTIs and emphasize that not all CoNS should be considered harmless.

Given its increasing association with SSTIs, and in particular hidradenitis suppurativa, isolation of *S lugdunensis* in wound or blood cultures should be taken seriously and treated promptly. Our patient presented with severe bilateral axillary hidradenitis suppurativa causing bacteremia. Patients with this inflammatory skin disease often present with painful abscesses and scarring, particularly in intertriginous areas. For many, it can be a chronic and debilitating disease. The exact pathophysiology remains unclear, but it can cause severe cellulitis, nodules, and abscesses. *S lugdunensis* has been identified in regions of the body rich in apocrine glands and has recently been implicated in infections in both healthy and immunosuppressed individuals.⁵ Several studies have explored the relationship between skin flora composition and hidradenitis suppurativa. Guet-Revillet and colleagues⁴ classified patients into 2 profiles: one of mixed anaerobes and another of *S lugdunensis*. The underlying pathogenicity of this organism may be related to biofilm and adherent protein production, resistance to lysozyme, and production of heat-stable hemolysin.⁶⁻⁸ Virulence factors produced by *S lugdunensis* in comparison to *S aureus* and other CoNS is summarized in the **Table**. *S lugdunensis* is a species of CoNS that can cause severe diseases, including native-valve endocarditis, osteomyelitis, abscesses, and bone and joint infections.⁶ When this pathogen causes endocarditis, the disease course can be fulminant and aggressive, leading to a high degree of valve destruction. Fortunately, *S lugdunensis* is susceptible to a wide range of antibiotics, including penicillin G.⁹ After our

Table. Virulence Factors Produced by *S lugdunensis* Compared With Other Common Staphylococcus Species⁶⁻⁸

SPECIES	GRAM STAIN	COAGULASE PRODUCTION	HEAT-STABLE HEMOLYSIN PRODUCTION	VWF-BINDING PROTEIN PRODUCTION	LYSOZYME RESISTANCE	BIOFILM PRODUCTION
<i>S lugdunensis</i>	+	-	+	+	+	+
<i>S saprophyticus</i>	+	-	-	-	-	+
<i>S epidermidis</i>	+	-	-	-	-	+
<i>S aureus</i>	+	+	+	+	+	+

Abbreviation: vWF, von Willebrand factor-binding protein

patient was found to have bacteremia, a transthoracic echocardiography scan was performed, results of which did not show evidence of endocarditis. Repeat blood cultures drawn within 48 hours of the initial positive cultures were clear after the initiation of antibiotics.

Patient outcome

Over the next few weeks, our patient clinically improved with decreased axillary erythema, pain, and swelling. She completed the prescribed course of antibiotics and was advised by her dermatologist to continue benzoyl peroxide washes daily and topical clindamycin application twice daily to prevent flares of hidradenitis suppurativa.

Conclusion

This case highlights the importance of recognizing that not all CoNS should be considered harmless. Given the virulence of *S lugdunensis* and its association with SSTIs, the authors felt that it was important to educate clinicians who frequently treat these conditions on the significance of this pathogen in causing invasive and suppurative infections. Patients with SSTIs found to have bacteremia with *S lugdunensis* require particular attention and prompt treatment to prevent deep-seated infections and poor outcomes.

REFERENCES

1. Miller LG, Eisenberg DF, Liu H, et al. Incidence of skin and soft tissue infections in ambulatory and inpatient settings, 2005-2010. *BMC Infect Dis.* 2015;15:362. doi:10.1186/s12879-015-1071-0

2. Edelsberg J, Taneja C, Zervos M, et al. Trends in US hospital admissions for skin and soft tissue infections. *Emerg Infect Dis.* 2009;15(9):1516-1518. doi:10.3201/eid1509.081228

3. Akiyama H, Kanzaki H, Tada J, Arata J. Coagulase-negative staphylococci isolated from various skin lesions. *J Dermatol.* 1998;25(9):563-568. doi:10.1111/j.1346-8138.1998.tb02459.x

4. Guet-Revillet H, Coignard-Biehler H, Jais JP, et al. Bacterial pathogens associated with hidradenitis suppurativa, France. *Emerg Infect Dis.* 2014;20(12):1990-1998. doi:10.3201/eid2012.140064

5. Pinheiro-Hubinger L, Moraes Riboli DF, Abraão LM, Pereira Franchi EPL, Ribeiro de Souza da Cunha ML. Coagulase-negative staphylococci clones are widely distributed in the hospital and community. *Pathogens.* 2021;10(7):792. doi:10.3390/pathogens10070792

6. Frank KL, Del Pozo JL, Patel R. From clinical microbiology to infection pathogenesis: how daring to be different works for *Staphylococcus lugdunensis*. *Clin Microbiol Rev.* 2008;21(1):111-133. doi:10.1128/CMR.00036-07

7. Otto M. Staphylococcal biofilms. *Curr Top Microbiol Immunol.* 2008;322:207-228. doi:10.1007/978-3-540-75418-3_10

8. Szabados F, Nowotny Y, Marlinghaus L, et al. Occurrence of genes of putative fibrinogen binding proteins and hemolysins, as well as of their phenotypic correlates in isolates of *S. lugdunensis* of different origins. *BMC Res Notes.* 2011;4:113. doi:10.1186/1756-0500-4-113

9. Taha L, Stegger M, Söderquist B. *Staphylococcus lugdunensis*: antimicrobial suscep-

tibility and optimal treatment options. *Eur J Clin Microbiol Infect Dis.* 2019;38(8):1449-1455. doi:10.1007/s10096-019-03571-6