

Symptomatic Nonruptured Abdominal Aortic Aneurysm

Geethika Thota, MD¹ • Hamza Ashraf² • Balaji Yegneswaran, MD³

A 68-year-old man with a medical history significant for hypertension and hyperlipidemia presented to our emergency department (ED) with intermittent abdominal pain, which had been present for 2 months. The episodes of abdominal pain were localized to the umbilical region, with each episode lasting for a couple of minutes and subsiding spontaneously.

The patient denied chest pain, back pain, shortness of breath, weakness, dizziness, or fever. His pain gradually began to worsen and became more constant, which prompted him to visit his primary care physician who referred the patient to the ED.

Physical examination

Upon presentation, the patient had a temperature of 36.6 °C, a heart rate of 69 beats/min, a respiratory rate of 18 breaths/min, a blood pressure of 159/92 mm Hg, an oxygen saturation of 98% on room air, and a body mass index of 27.7 kg/m².

Results of a physical examination showed a patient in no acute distress.

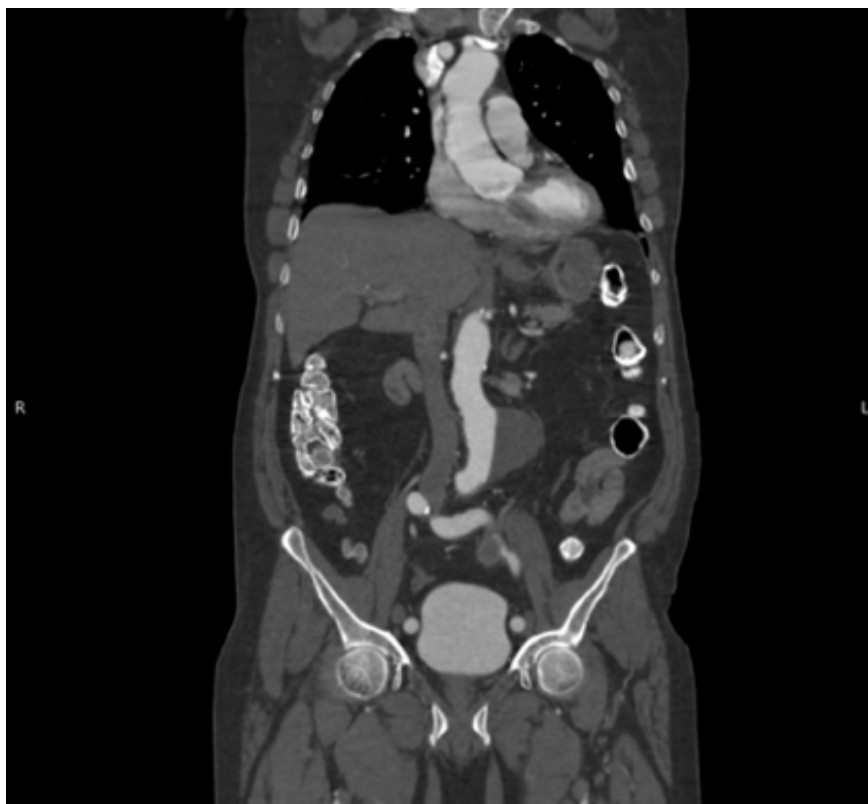

Figure 1. A computed tomography angiogram of the chest, abdomen, and pelvis revealed a 6.2-cm infrarenal abdominal aortic aneurysm with a mural thrombus with no evidence of rupture.

AFFILIATIONS:

¹Resident Physician, Department of Internal Medicine, Saint Peter's University Hospital, New Brunswick, New Jersey

²Medical Student, Saint Peter's University Hospital, New Brunswick, New Jersey

³Critical Care Medicine, Saint Peter's University Hospital, New Brunswick, New Jersey

CITATION:

Thota G, Ashraf H, Yegneswaran B. Symptomatic nonruptured abdominal aortic aneurysm. *Consultant*. Published online November 19, 2021. doi:10.25270/con.2021.11.00010

Received July 6, 2021. Accepted July 26, 2021.

DISCLOSURES:

The authors report no relevant financial relationships.

CORRESPONDENCE:

Geethika Thota, MD, Saint Peter's University Hospital, 254 Easton Avenue, New Brunswick, NJ 08901 (prathima.thota95@gmail.com)

His pulses were intact and symmetrical in the upper and lower extremities. His abdomen was soft and nondistended with no tenderness. No pulsatile mass was appreciated.

Diagnostic testing

Results of initial laboratory tests were within normal limits. A computed tomography angiogram of the chest, abdomen, and pelvis was conducted, results of which showed a 6.2-cm infrarenal abdominal aortic aneurysm with a mural thrombus with no evidence of rupture (Figure 1), a 3.6-cm left common iliac

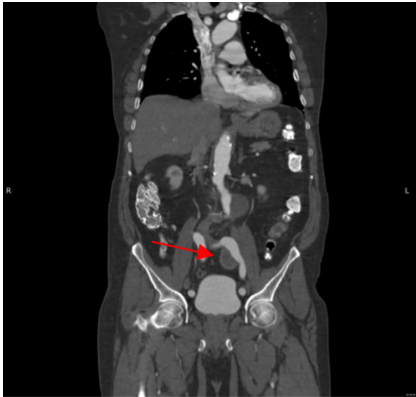


Figure 2. A computed tomography angiogram of the chest, abdomen, and pelvis revealed a 3.6-cm left common iliac artery aneurysm with a mural thrombus with no evidence of rupture.

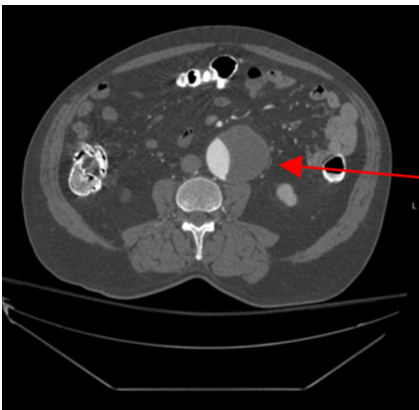


Figure 3. A computed tomography scan (axial) showed an abdominal aortic aneurysm with no evidence of rupture.

Table. Risk Factors Associated With Abdominal Aortic Aneurysms³

Male sex
Older age (> 60)
Atherosclerosis
Hypertension
Smoking history
Family history of AAA
White race

artery aneurysm with a mural thrombus with no evidence of rupture (Figure 2), and a mild aneurysmal dilatation of the thoracic aorta (Figure 3).

The patient underwent intrarenal embolization of the left internal iliac artery for type II Endoleak prevention and

subsequently underwent an endovascular aortic aneurysm and left common iliac artery repair.

Patient outcome

The patient tolerated the procedures well and was discharged home on trimethoprim-sulfamethoxazole combination antibiotic for 4 days as prophylaxis for the stent graft placement. The patient remained asymptomatic on outpatient follow-up.

Discussion

Abdominal aortic aneurysms (AAAs) are prevalent in 5% to 7% of patients aged older than 60 years in the United States.¹ Although it is usually asymptomatic and clinically silent, the usual presenting symptoms could be abdominal pain, chest pain, or back pain depending on the size and location of the aneurysm. The most lethal complication of an AAA is the rupture of an aneurysm, which occurs in one-third of patients, with a mortality rate ranging from 30% to 50% after presentation.² In this paper, we described a case of a 68-year-old man who presented with intermittent abdominal pain and was discovered to have an abdominal aortic aneurysm. Interestingly, this patient was a lifetime nonsmoker.

AAA is a potentially life-threatening condition. The presentation is asymptomatic in up to 75% of cases.³ The risk factors associated with abdominal aortic aneurysmal disease include male sex, age older than 60 years, diagnosis of atherosclerosis, diagnosis of hypertension, smoking history, family history of AAA, and White race (Table).³

Because of the known risk factors for development of an abdominal aortic aneurysm, the US Preventive Service Task Force recommends a one-time screening for AAA with abdominal ultrasonography in men between aged 65 to 75 years who have a history of smoking.⁴ Additionally, the screening and identification of abdominal aortic aneurysms by primary care physicians can have a significant impact on the patient's survival rate.⁵ Pa-

tients with stable AAAs should undergo regular surveillance or operative intervention depending on aneurysmal size. Surgical intervention by open or endovascular repair is the primary option and is typically reserved for aneurysms sized 5.5 cm in diameter or greater, or those that are rapidly growing (more than 0.6 to 0.8 cm per year).⁶

Cryptic presentations with AAA are common, with 60% of aneurysms initially misdiagnosed as diverticulitis, gastritis, gastroesophageal reflux disease, musculoskeletal pain, or renal colic.⁷ Therefore, it is recommended to have a low threshold of clinical suspicion for performing a bedside abdominal ultrasonography scan in patients aged 50 to 60 years presenting with abdominal pain or back pain.⁸ A ruptured abdominal aneurysm is a medical emergency presenting with sudden and severe abdominal or back pain, hypotension, dizziness, and loss of consciousness.⁹ It is associated with high prehospitalization mortality, with 8 out of 10 patients either dying before they reach the hospital or dying perioperatively.¹⁰

REFERENCES

1. Santilli JD, Santilli SM. Diagnosis and treatment of abdominal aortic aneurysms. *Am Fam Physician.* 1997;56(4):1081-1090.
2. Marston WA, Ahlquist R, Johnson G Jr, Meyer AA. Misdiagnosis of ruptured abdominal aortic aneurysms. *J Vasc Surg.* 1992;16(1):17-22. <https://doi.org/10.1067/mva.1992.34344>
3. de Boer NJ, Knaap SF, de Zoete A. Clinical detection of abdominal aortic aneurysm in a 74-year-old man in chiropractic practice. *J Chiropr Med.* 2010;9(1):38-41. <https://doi.org/10.1016/j.jcm.2009.12.002>
4. Final Recommendation Statement. Abdominal Aortic Aneurysm: Screening. US Preventive Services Task Force. Published December 10, 2019. Accessed November 8, 2021. <https://www.uspreventiveservicestaskforce.org/uspstf/recommendation/abdominal-aortic-aneurysm-screening>
5. Dalman RL. The 2019 update of the European abdominal aortic aneurysm guidelines. *J Vasc Surg.* 2019;69(3):633-634. <https://doi.org/10.1016/j.jvs.2018.12.008>

6. Upchurch GR Jr, Schaub TA. Abdominal aortic aneurysm. *Am Fam Physician*. 2006;73(7):1198-1204. <https://www.aafp.org/afp/2006/0401/p1198.html>
7. Sinha Y. Elderly patient with ureteric colic: suspect leaking aneurysm. *BMJ Case Rep*. 2013;2013:bcr2012008617. <https://doi.org/10.1136/bcr-2013-008617>
8. Lee SI, Mueller PR, Thrall JH. Re: "managing incidental findings on abdominal CT: White Paper of the ACR Incidental Findings Committee". *J Am Coll Radiol*. 2011;8(2):e3-e4. <https://doi.org/10.1016/j.jacr.2010.11.004>
9. Powell JT, Brown LC, Greenhalgh RM, Thompson SG. The rupture rate of large abdominal aortic aneurysms: is this modified by anatomical suitability for endovascular repair? *Ann Surg*. 2008;247(1):173-179. <https://doi.org/10.1097/sla.0b013e3181557d2a>
10. Reimerink JJ, van der Laan MJ, Koelemay MJ, Balm R, Legemate DA. Systematic review and meta-analysis of population-based mortality from ruptured abdominal aortic aneurysm. *Br J Surg*. 2013;100(11):1405-1413. <https://doi.org/10.1002/bjs.9235>